

Template guided transperineal saturation biopsy of the prostate: lessons for focal and urethra-sparing high-dose-rate brachytherapy for localized prostate cancer

Sergey Nikolaevich Novikov, MD, PhD¹, Prof. Sergey Vasilevich Kanaev, MD, PhD¹, Roman Vladimirovich Novikov, MD, PhD¹, Nikolay Dmitrievich Illin, MD¹, Anna Sergeevna Artemieva, MD², Alexander Olegovich Ivantsov, MD², Evgeniy Alexandrovich Piskunov, MD¹, Mariya Yurievna Gotovchikova, MD¹

¹Department of Radiation Oncology and Radiology, ²Pathomorphology Department, N.N. Petrov Institute of Oncology, St. Petersburg, Russia

Abstract

Purpose: The aim of this work is to evaluate results of prostate transperineal saturation biopsy as a guide for focal high-dose-rate brachytherapy in patients with prostate cancer (PCa).

Material and methods: Template guided saturation biopsy was performed in 67 primary patients with suspicion for prostate cancer. Biopsy was performed under ultrasonography (US) control with the help of brachytherapy grid and 5 mm distance between samples. We put special attention for accurate sampling of prostate in periurethral region. The number of cores varied from 17 to 81 (average 36 cores). Finally, in 40 patients with confirmed prostate cancer results of biopsy were used for brachytherapy planning.

Results: Saturation biopsy revealed prostate cancer in 40 of 67 evaluated patients. The extent of biopsy core involvement varied from 5% to 100% (average: 57%). Focal nature of PCa (single unilateral tumor nodule) was diagnosed in 10 (25%), multifocal – in another 30 (75%) patients. Hemigland invasion was mentioned in 12 (30%) cases. Saturation biopsy detected PCa in periurethral cores in 27 (67.5%) of 40 evaluated patients. In 10 patients, the extent of involvement in periurethral cores varied between 10% and 50%; in another, 17 observations exceeded 50%. According to results obtained on saturation biopsy, we performed HDR brachytherapy with “urethra low dose tunnel” ($D_{10ur} \leq 80-90\%$) in 13 patients with noninvolved periurethral cores. Theoretically, hemigland brachytherapy was possible in 12 of 40 evaluated patients with PCa.

Conclusions: In low risk patients with PCa results of template guided saturation biopsy indicates high frequency (75%) of multifocal disease and high probability (67.5%) of periurethral invasion. Suitable candidates for focal HDR brachytherapy or irradiation with additional sparing of urethra can be effectively determined with the help of saturation biopsy.

J Contemp Brachytherapy 2016; 8, 2: 110-115

DOI: 10.5114/jcb.2016.59336

Key words: brachytherapy, HDR, prostate cancer, saturation biopsy.

Purpose

Radiation therapy is an established non-invasive treatment for patients with localized prostate cancer (PCa) that is recommended in modern guidelines as an attractive alternative to radical surgery [1,2]. Its most important advantage is a possibility of achieving a reliable local control comparable to results obtained after prostatectomy, while significantly reducing the serious adverse effects of treatment [3,4,5]. Analysis of the literature points to the obvious correlation between the rate of local control and biological effective dose delivered to the prostate.

In particular, the results of two largest meta-analyses [6,7] indicate a significant increase in biochemical and clinical disease-free survival in cases where the quantity of biologically effective dose to the tumor and to the prostate was higher than 200 Gy ($\alpha/\beta = 1.5$). High-dose-rate (HDR) brachytherapy is recognized as one of the most promising methods in PCa treatment, as it not only provides the required accuracy of dose delivery, but allows a steep dose gradient between the target organ and the surrounding normal tissue [1,2,3,4]. This feature of HDR brachytherapy enables achieving reliable control while reducing the risk of adverse effects of treatment.

Address for correspondence: Sergey Nikolaevich Novikov, MD, PhD, Department of Radiation Oncology and Radiology, N.N. Petrov Institute of Oncology, St. Petersburg, 68 Leningradskaya St., St. Petersburg, Russia, phone: +7 950043796, e-mail: krokon@mail.ru

Received: 19.11.2015

Accepted: 14.03.2016

Published: 27.04.2016

Particularly, the comparison of results of external-beam radiotherapy and brachytherapy for PCa showed the reduction in the rate of major rectal complications from 10-20% [8] to 1-8% [9,10], respectively. However, the use of standard methods of HDR brachytherapy delivering relatively uniform dose to the entire prostate are associated with the inevitable increase in genitourinary toxicity [11]. This is primarily due to topographic features of the prostatic urethra located within the prostate gland and, therefore, exposed to radiation in high therapeutic doses. According to the recent reports, the incidence of grade ≥ 2 genitourinary toxicity after HDR brachytherapy for prostate cancer is around 9-10% [3,10], and reaches 12-19% in some publications [12,13]. Therefore, in patients with low risk localized (stage T1-T2a) PCa, the research have been directed toward different methods of focal prostate brachytherapy, which can varied from hemigland irradiation to focal therapy directly to the tumor foci [11,14]. Considering the high incidence of multifocal pattern of prostate involvement, in our Institute we abounded classic focal HDR brachytherapy for patients with PCa. Nonetheless, low risk patients in our department receive HDR brachytherapy to the whole prostate with a substantial decrease in exposure (to 80% of the therapeutic dose) to the urethra and prostatic tissue in the periurethral region (Figure 1). An important stage in the preparation for this treatment option is a saturation biopsy, which allows to clarify the PCa topography, specifically to rule out the presence of PCa in biopsy cores obtained from the periurethral region. The results of saturation biopsy that was used for HDR brachytherapy planning were analyzed in the present study.

Material and methods

From July 2012 to August 2015, a total of 174 men were referred to the N.N. Petrov Institute of Oncology

for participation in HDR interstitial brachytherapy program for localized prostate cancer. Eligibility criteria included low- or intermediate-risk localized prostate cancer (T1-T2cN0M0, PSA ≤ 20 ng/ml, and a Gleason score ≤ 7). Patients were considered ineligible for the procedure if they had International Prostate Symptom Score (IPSS) > 15 and were unable to assume the lithotomy position, or had any contraindication to receive anesthesia.

Among these 174 patients, 67 had indications for transperineal saturation biopsy (TPSB) because of previous negative transrectal ultrasound biopsy and/or rising levels of prostate-specific antigen (PSA). Members of the brachytherapy working group agreed that in all these patients the results of TPSB would be used for HDR brachytherapy planning. The study was approved by Institutional Ethics Committee. Informed consents were obtained from all patients.

Transperineal saturation biopsy was performed under spinal anesthesia. The number of cores per biopsy varied between 17 to 81 depending on the prostate volume. In one patient, 17 biopsy cores were obtained that did not meet the standard criteria of SPB (21 or more cores). However, a small prostate volume (17.9 ml) allowed to include him in the study, since the key principle of the procedure (its systemic nature giving the opportunity to obtain material from all parts of the prostate) was adhered to.

All patients diagnosed with PCa based on TSPB findings subsequently underwent HDR brachytherapy in a monotherapy regime. Standard procedure with 3D ultrasound (US) guidance of the needles was performed on Microselectron afterloader equipped with Oncentra Prostate planning system (Elekta AB, Stockholm, Sweden). Risk stratification followed National Comprehensive Cancer Network (NCCN) criteria's for prostate cancer risk assessment [15].

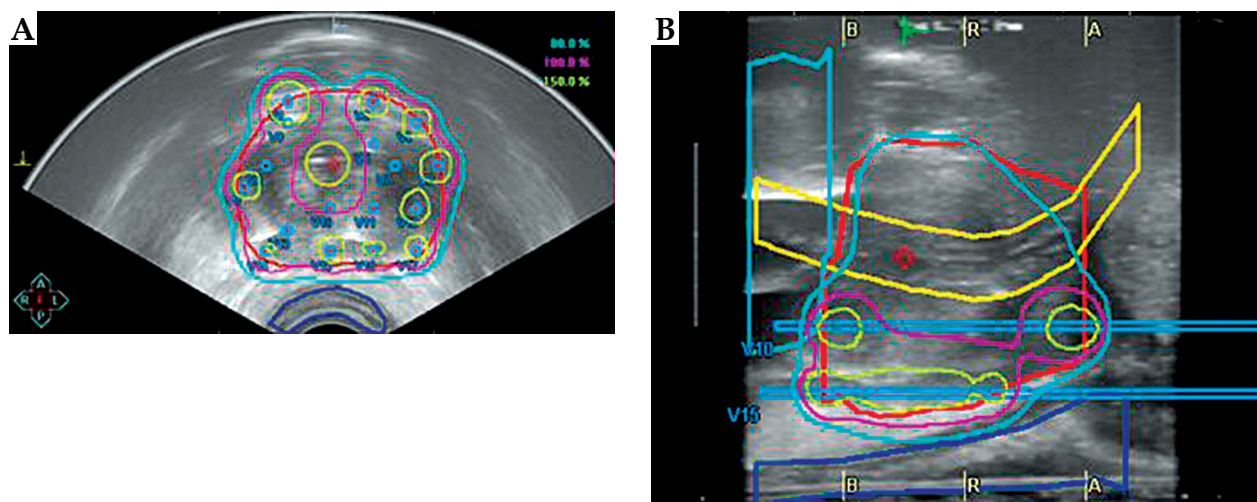


Fig. 1. Dose plan generated for whole prostate high-dose-rate brachytherapy with decrease in exposure to the urethra. Planning volumes: red - prostate, yellow - urethra, navy blue - rectum, light blue - bladder. Dose distribution: navy blue - 80% isodose, pink - 100% isodose, yellow - 150% isodose. **A)** Transaxial view demonstrated reduced absorbed dose in urethra and adjacent prostate tissue (covered by 80% isodose). **B)** Sagittal view demonstrated full (covered by 100% isodose) dose absorbed by posterior (lower) segment of prostate including peripheral zone, and reduced dose to the urethra (covered by 80% isodose) and anterior (upper) segment of the prostate

Transperineal saturation biopsy technique

Transperineal saturation biopsy was performed using endorectal US scanner (BK Medical, Denmark), allowing two (2D) and three (3D) dimensional transrectal prostate scanning with a 7.5 MHz probe placed on a stepper. The direction of biopsy needle insertion was preplanned using the calibrated brachytherapy template grid fixed to the stepper. Biopsy was performed with 18 G needles (penetration depth: 22 mm). Balloon 2 channel catheter was inserted into the bladder with aerated gel placed within one channel to enable US visualization of urethra.

Defining the prostate and urethra borders in transverse scanning was followed by biopsy planning with 5 mm distance between punctures. Particular attention was paid to obtain biopsies in periurethral zone. For this, the prostatic urethra image was placed in the center of the template grid and corresponded to the sagittal plane indicated by the letter D. Further, biopsy cores were obtained under US control in the sagittal plane.

The main stage of the procedure was to obtain biopsy cores in the periurethral zone (PUZ) located lateral and below the urethra. This structure as an integral notion partly including all histological zones of the prostate (according to McNeal [16]), and its anatomic regions (from the apex to the base) was specified by technical features of HDR brachytherapy (Figure 2). The number of cores obtained from PUZ correlated with the size of prostate varied from 6 to 18 (average: 10.4).

High-dose-rate brachytherapy as a monotherapy was performed in 147 patients. The dose to the whole gland was delivered in 3 fractions of 11.5 Gy or 2 fractions of 13 Gy separated by 14-21 days. The dose distribution was created by inverse optimization on Oncentra Prostate (Elekta AB, Stockholm, Sweden) planning system. According to standard recommendations [1,3,4], the whole prostate should be covered by 90% isodose ($D_{90} > 100\%$), and

the volume of prostate receiving 100% of the prescribed dose should be more than 93% ($V_{100} > 93\%$). The highest dose covering 10% of the prostatic urethra should be kept below 110% ($D_{10} < 110\%$) and maximum dose (D_{max}) for urethra should never exceed 120%. Maximum dose to the rectum and bladder should be kept below 75% of therapeutic dose ($D_{2cc} < 75\%$). In patients with low risk (T1-2a, PSA < 11, Gleason 6) prostate cancer without invasion of PUZ, we performed urethra-sparing HDR brachytherapy. In this case, we significantly changed constraints for urethra: $D_{10} < 80-90\%$, $D_{max} < 100\%$. According to urethra-sparing prescription algorithm, the peripheral zone should be mandatorily treated in full therapeutic dose ($V_{100} PZ > 98\%$, $D_{90} PZ > 105\%$) but the coverage of the whole prostate can be lower in comparison to standard recommendation.

Results

The average age of patients was 63 years (range: 46-78 years), mean prostate volume – 43.7 ml (range: 17.9-110.0 ml), and the average number of biopsies per procedure – 36 (range: 17-81).

Pathomorphological analysis of biopsy material detected prostate adenocarcinoma in 40 (59.7%) of 67 patients. The extent of biopsy core involvement ranged from 5% to 100% (mean: 57%). Biological activity of the tumor according to Gleason score was distributed as follows: Gleason score 6 in 21 (52.5%), Gleason score 7 in 13 (32.5%), and Gleason score 8 in 6 (15%) patients.

As mentioned above, the information about the type (focal, multifocal, unilateral, or bilateral) and topography of PCa detected by TPSB procedure was of particular importance for HDR brachytherapy planning. The focal nature of the PCa (single unilateral tumor nodule manifested as one or several adjacent positive biopsy cores) was identified in 10 (25%) of 40 cases. The remaining

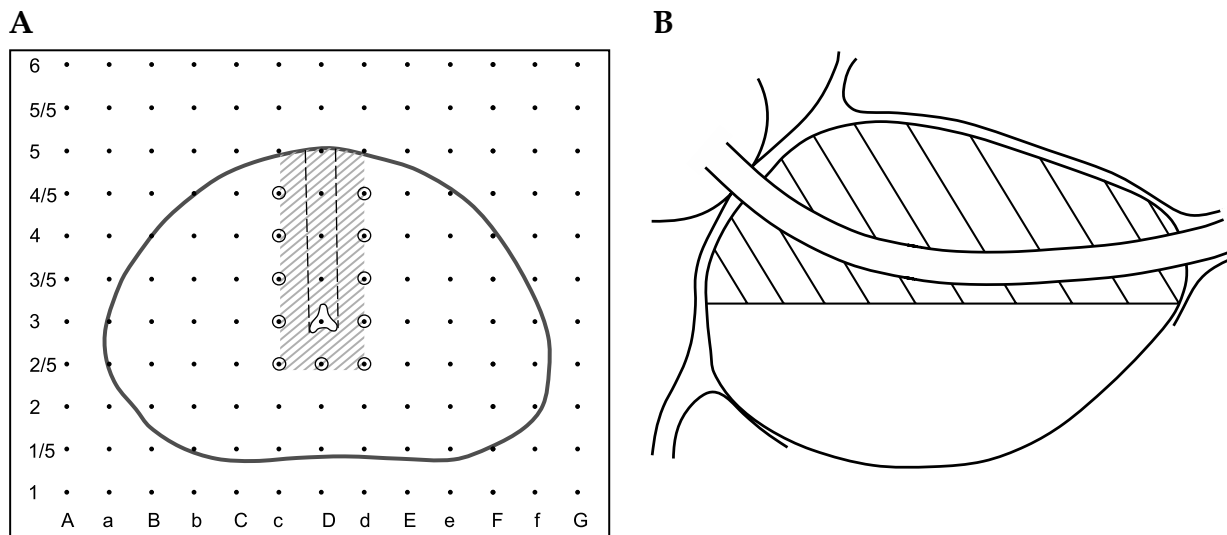


Fig. 2. Scheme of biopsy taking in periurethral zone (PUZ). **A)** Periurethral biopsy sampling scheme (marked with circles). The topography of the prostate urethra coincides with D3 point of grid template, the projection of the urethra in the transverse scan is indicated by a dashed line. **B)** Sagittal scan of the prostate: periurethral zone is indicated by the shaded area. All obtained biopsy cores were labeled (according to position on the grid; apical or basal location). Biopsy cores obtained in PUZ were marked separately

30 (75%) patients had multifocal PCa: two separate foci in 14 (46.7%) cases, three - in 11 (36.7%), and four or more separate lesions - in 5 (16.6%) patients.

Involvement of one of the lobes of the prostate gland was found in 12 (30%) patients, and tumor areas in both lobes were diagnosed in 28 (70%) cases. The presence of adenocarcinoma in one lobe usually took place in cases of focal PCa (10 of 12 patients), and the remaining two cases were characterized by two separate foci localized in one lobe.

Adenocarcinoma in biopsies obtained from PUZ was detected in 27 (67.5%) of 40 patients with PCa. The percentage of this prostate portion involvement was assessed taking into account two factors: maximum volume of biopsy core involvement (%) and positive core ratio for paraurethral zone - ratio (%) of the number of cores containing adenocarcinoma to the total number of cores obtained from PUZ. The extent of involvement of biopsy cores taken from PUZ ranged from 50% to 100% in 17 (62.9%) patients, and did not exceed 50% in the remaining 10 (37.1%) cases. Positive core ratios were: 10% in 4 (14.8%), 10-30% in 13 (48.2%), 30-50% in 7 (25.9%), and 50% in 3 (11.1%) cases.

Discussion

High clinical efficacy of HDR brachytherapy as a monotherapy of patients with low- and intermediate-risk localized PCa and as a component of combined treatment of high-risk patients is confirmed by numerous clinical studies [9,17,18]. The standard HDR brachytherapy technique suppose fractionated irradiation (from 2 to 6 fractions) of the whole prostate with biologically effective dose equivalent to 200 Gy ($\alpha/\beta = 1.5$), or higher. Recent trends in HDR brachytherapy of PCa are moving toward reducing the number of fractions with simultaneous increase in fraction size. Short treatment time and decreased number of implantations are the main attractions of this strategy. Increased risk of toxicity, first of all genitourinary toxicity, is recognized as the main threat of such extreme hypofractionation. A retrospective analysis of 474 patients who underwent HDR brachytherapy for PCa [19] demonstrated a 12% risk of obstructive disorders occurring during the first 6 years after the end of radiotherapy, with increase up to 15.3% in patients that receive hypofractionated treatment.

Cendales *et al.* [18] analyzed the toxicity profile of HDR monotherapy by 2 fractions of 12.5 Gy each. They noted a significant relationship between radiation doses administered to the urethra and the risk of genitourinary complications. The authors reported a fourfold increased risk of urinary toxicity in patients, which received more than 111% of the prescribed dose in 1 cm of urethra. Register *et al.* [20] mentioned significant correlation between urinary morbidity and dose to the external and internal urinary sphincters. Pinkawa *et al.* [21] recommended to restrict the dose to the bladder neck and urethral sphincter below 170-190 Gy, in order to preserve a satisfactory urinary function.

To reduce radiation exposure to normal tissues, primarily to the prostatic urethra, and reduce the toxicity

of the treatment, several groups proposed the methods of focal HDR brachytherapy for PCa. This approach assumes irradiation of only clinically significant, so-called dominant tumor lesions, or hemi-gland irradiation of the tumor-containing lobe. The key point in the concept of focal therapy for PCa is the assumption that, despite the high incidence of multifocal character of prostate invasion, the ability to achieve a stable control over disease is determined by effective treatment of the largest, so-called dominant focus with the volume above 0.5 cm³. It was stated [22,23] that dominant (index) lesion represent the largest (80-90% of the whole tumor volume) and the most aggressive part of the tumor, and other lesions that have not or very small clinical significance.

One of the most important advantages of focal treatment for prostate cancer is reducing the risk of damage to normal tissues surrounding the tumor. Dosimetric data analysis made by Mason *et al.* [24] showed that after conversion from whole prostate irradiation to hemigland HDR brachytherapy, there was no significant reduction in radiation dose to the urethra: D_{10} , D_{30} and D_{max} values were reduced only by 2-6%. On the contrary, when planning focal therapy, authors observed a significant reduction in absorbed dose to the urethra and bladder: mean reduction for urethra D_{10} - 53%, for bladder D_{2cm^3} - 64%. According to the results of Peters *et al.* [25], salvage brachytherapy with reduced doses to the urethra and bladder causes significant reduction of severe (grade ≥ 3) genitourinary toxicity: from 38% mentioned after total gland irradiation to 5% after focal brachytherapy.

Identification of the exact tumor margins is essential for effective focal treatment. At recent time, multiparametric prostate MRI is most commonly used to visualize the dominant lesions [26]. However, there is an evidence of bafflements in clinical application of MRI data for focal therapy planning [27]. According to recent data [24,28,29], MRI derived tumor volume must be expanded by 4.5-8 mm in order to include all treatable (≥ 0.5 cm³) lesions. In fact, the use of proposed margins for focal therapy to dominant lesions 1.0-1.5 cm in diameter makes it equivalent to hemigland irradiation.

Taking into account the limited capabilities of MRI in defining the margins of the dominant focus, we found interesting the data of Epstein *et al.* [30] who investigated diagnostic performance of saturation biopsy. In the group of 103 men, authors compared results of saturation biopsy (average: 44 cores) with postoperative histological examination of removed prostates. They concluded that saturation biopsy "provides accurate predictability of prostate tumor volume and grade", and specially mentioned its high specificity (95.5%) in differentiation significant and insignificant cancer. It was shown in earlier studies that 12 biopsy cores [31] and 24 transrectal biopsy cores [32,33] were not sufficiently accurate to predict uni- or bilateral dominant prostate cancer. In order to be more accurate in the present study, we used template guided transperineal biopsy with 5 mm step between cores and higher average core number (33 cores).

Our findings indicate the high incidence of multifocal involvement of the prostate in most (75%) of evaluated patients. Moreover, tumor invasion was con-

found in one half of the prostate only in 30% of patients. The clinical significance of small (less than 0.5 cm³) tumor lesions in multifocal PCa of the prostate gland is not fully understood. Many authors believe that they do not significantly affect the prognosis of the disease [22,23]. On the other hand, Huang *et al.* [34] reported that small satellite lesions can be presented with highest Gleason patterns in 11% of patients with prostate cancer. In this case, the treatment of all cancer lesions seems obligatory. In addition, our experience in the use of focal therapy for patients with localized low-risk PCa indicates the high (38%) probability of disease progression within 6 months after the end of treatment [35]. In this regard, since 2014 in low risk patients we began to use brachytherapy to the whole prostate gland with simultaneous substantial reduction (to 80% of the planned dose) of absorbed dose to the urethra and bladder neck. This strategy to some extent resembles so-called Kiel protocol [36]. Cunha *et al.* [37] called it "urethra low-dose tunnels" and demonstrated 40% reduction of urethral V₁₀₀ with the help of this technique. Our analysis of saturation biopsy data indicates high frequency (70%) of neoplastic involvement of so-called periurethral region. Magnetic resonance imaging and pathological study of surgical specimens from patients with PCa also indicate 28.5-40% risk of central gland invasion by PCa [24,28]. This necessitates extreme caution in selection of candidates for PCa brachytherapy with creation of low-dose tunnels around the urethra. We currently use this option of HDR brachytherapy only in patients who underwent saturation biopsy at a diagnostic stage, and only in those cases when histological report indicated no signs of tumor in cores obtained from periurethral region.

Conclusions

Results of transperineal saturation biopsy performed in patients with low intermediate-risk localized prostate cancer indicate high frequency (75%) of multifocal disease and high probability (67.5%) of periurethral region involvement. The presented data show that focal HDR brachytherapy and even irradiation with the urethra low-dose tunnel must be performed with caution. In these cases, saturation biopsy can give additional information for brachytherapy planning.

Disclosure

Authors report no conflict of interest.

References

- Hoskin PJ, Colombo A, Henry A et al. GEC/ESTRO recommendations on high dose rate afterloading brachytherapy for localized prostate cancer: an update. *Radiother Oncol* 2013; 107: 325-332.
- Wolff RF, Ryder S, Bossi A et al. A systematic review of randomized controlled trials of radiotherapy for localized prostate cancer. *Eur J Cancer* 2015; 51: 2345-2367.
- Demanes DJ, Ghilezan MI. High-dose-rate brachytherapy as monotherapy for prostate cancer. *Brachytherapy* 2014; 13: 529-541.
- Yoshioka Y, Suzuki O, Otani Y et al. High-dose-rate brachytherapy as monotherapy for prostate cancer: technique, rationale and perspective. *J Contemp Brachytherapy* 2014; 6: 91-98.
- Skowronek J. Low-dose-rate or high-dose-rate brachytherapy in treatment of prostate cancer – between options. *J Contemp Brachytherapy* 2013; 6: 91-98.
- Zaorsky NG, Palmer JD, Hurwitz MD et al. What is the ideal radiotherapy dose to treat prostate cancer? A meta-analysis of biologically equivalent dose escalation. *Radiother Oncol* 2015; 115: 295-300.
- Martinez AA, Gonzalez J, Ye H, et al. Dose escalation improves cancer-related events at 10 years for intermediate- and high-risk prostate cancer patients treated with hypofractionated high-dose-rate boost and external beam radiotherapy. *Int J Radiat Oncol Biol Phys* 2011; 79: 363-370.
- D'Ambrosio DJ, Pollack A, Harris EE et al. Assessment of external beam radiation technology for dose escalation and normal tissue protection in the treatment of prostate cancer. *Int J Radiat Oncol Biol Phys* 2008; 70: 671-677.
- Galalae RM, Zakikhany NH, Geiger F et al. The 15-year outcomes of high-dose-rate brachytherapy for radical dose escalation in patients with prostate cancer – a benchmark for high-tech external beam radiotherapy alone? *Brachytherapy* 2014; 13: 117-122.
- Hoskin P, Rojas A, Ostler P et al. High-dose-rate brachytherapy alone given as two or one fraction to patients for locally advanced prostate cancer: acute toxicity. *Radiother Oncol* 2014; 110: 268-271.
- Kamrava M, Chung MP, Kayode O et al. Focal high-dose-rate brachytherapy: a dosimetric comparison of hemigland vs. conventional whole-gland treatment. *Brachytherapy* 2013; 12: 434-441.
- Pellizzon AC, Salvajoli JV, Maia MA et al. Late urinary morbidity with high dose prostate brachytherapy as a boost to conventional external beam radiation therapy for local and locally advanced prostate cancer. *J Urol* 2004; 171: 1105-1108.
- Aluwini S, Busser WM, Alemayehu WG et al. Toxicity and quality of life after high-dose-rate brachytherapy as monotherapy for low- and intermediate-risk prostate cancer. *Radiother Oncol* 2015; 117: 252-257.
- Banerjee R, Park SJ, Anderson E et al. From whole gland to hemigland to ultra-focal high-dose-rate prostate brachytherapy: a dosimetric analysis. *Brachytherapy* 2015; 14: 366-372.
- Mohler J, Bahnson RR, Boston B et al. NCCN clinical practice guidelines in oncology: prostate cancer. *J Natl Compr Canc Netw* 2010; 8: 162-200.
- McNeal JE. Regional morphology and pathology of the prostate. *Am J Clin Pathol* 1968; 49: 347-357.
- Zamboglou N, Tselis N, Baltas D et al. High-dose-rate interstitial brachytherapy as monotherapy for clinically localized prostate cancer: treatment evolution and mature results. *Int J Radiat Oncol Biol Phys* 2013; 85: 672-678.
- Cendales R, Alwers E, Cifuentes J et al. High-dose-rate brachytherapy delivered in two fractions as monotherapy for low-risk prostate cancer. *J Contemp Brachytherapy* 2015; 7: 10-16.
- Sullivan L, Williams SG, Tai KH et al. Urethral stricture following high dose rate brachytherapy for prostate cancer. *Radiother Oncol* 2009; 91: 232-236.
- Register SP, Kudchadker RJ, Levy LB et al. An MRI-based dose – response analysis of urinary sphincter dose and urinary morbidity after brachytherapy for prostate cancer in a phase II prospective trial. *Brachytherapy* 2013; 12: 210-216.
- Pinkawa M, Fishedick K, Piroth MD et al. Health-related quality of life after permanent interstitial brachytherapy for prostate cancer: correlation with postimplant CT scan parameters. *Strahlenther Onkol* 2006; 182: 660-665.

22. Ahmed HU, Moore C, Emberton M. Minimally-invasive technologies in uro-oncology: the role of cryotherapy, HIFU and photodynamic therapy in whole gland and focal therapy of localized prostate cancer. *Surg Oncol* 2009; 18: 219-232.
23. Eggener S, Salomon G, Scardino PT et al. Focal therapy for prostate cancer: possibilities and limitations. *Eur Urol* 2010; 58: 57-64.
24. Mason J, Al-Qaisieh B, Bownes P et al. Dosimetry modeling for focal high-dose-rate prostate brachytherapy. *Brachytherapy* 2014; 13: 611-617.
25. Peters M, van der Voort van Zyp J, Hoekstra C et al. Urethral and bladder dosimetry of total and focal salvage Iodine-125 prostate brachytherapy: Late toxicity and dose constraints. *Radiother Oncol* 2015; 117: 262-269.
26. Muller BG, van den Bos W, Pinto PA et al. Imaging modalities in focal therapy: patient selection, treatment guidance, and follow-up. *Curr Opin Urol* 2014; 24: 218-224.
27. Steenbergen P, Haustermans K, Lerut E et al. Prostate tumor delineation using multiparametric magnetic resonance imaging: Inter-observer variability and pathology validation. *Radiother Oncol* 2015; 115: 186-190.
28. Mason J, Al-Qaisieh B, Bownes P et al. Multi-parametric MRI-guided focal tumor boost using HDR prostate brachytherapy: a feasibility study. *Brachytherapy* 2014; 13: 137-145.
29. Anwar M, Westphalen AC, Jung AJ et al. Role of endorectal MR imaging and MR spectroscopic imaging in defining treatable intraprostatic tumor foci in prostate cancer: quantitative analysis of imaging contour compared to whole-mount histopathology. *Radiother Oncol* 2014; 110: 303-308.
30. Epstein JI, Sanderson H, Carter HB et al. Utility of saturation biopsy to predict insignificant cancer at radical prostatectomy. *Urology* 2005; 66: 356-360.
31. Sinnott M, Falzarano SM, Hernandez AV et al. Discrepancy in prostate cancer localization between biopsy and prostatectomy specimens in patients with unilateral positive biopsy: implications for focal therapy. *Prostate* 2012; 72: 1179-1186.
32. Abdollah F, Scattoni V, Raber M et al. The role of transrectal saturation biopsy in tumour localization: pathological correlation after retropubic radical prostatectomy and implication for focal ablative therapy. *BJU Int* 2011; 108: 366-371.
33. Falzarano SM, Zhou M, Hernandez AV et al. Can saturation biopsy predict prostate cancer localization in radical prostatectomy specimens: a correlative study and implications for focal therapy. *Urology* 2010; 76: 682-687.
34. Huang CC, Deng FM, Kong MX et al. Re-evaluating the concept of "dominant/index tumor nodule" in multifocal prostate cancer. *Virchows Arch* 2014; 464: 589-594.
35. Nosov A, Turkevich V, Cheng C et al. Focal MRI-guided focused ultrasound treatment of localized low-risk prostate cancer. *J Ther Ultrasound* 2014; 2 (Suppl 1): A7.
36. Kovács G, Melchert C, Sommerauer M et al. Intensity modulated high-dose-rate brachytherapy boost complementary to external beam radiation for intermediate- and high-risk localized prostate cancer patients - how we do it in Lübeck/Germany. *Brachytherapy* 2007; 6: 142-148.
37. Cunha JA, Pouliot J, Weinberg V et al. Urethra low-dose tunnels: validation of and class solution for generating urethra-sparing dose plans using inverse planning simulated annealing for prostate high-dose-rate brachytherapy. *Brachytherapy* 2012; 11: 348-353.